

## CLINICAL REPORT

# Fractional Microneedling Radiofrequency Treatment for Acne-related Post-inflammatory Erythema

Seonguk MIN<sup>1,2#</sup>, Seon Yong PARK<sup>1,2#</sup>, Ji Young YOON<sup>2</sup>, Hyuck Hoon KWON<sup>1,2</sup> and Dae Hun SUH<sup>1,2</sup>

<sup>1</sup>Department of Dermatology, Seoul National University College of Medicine, <sup>2</sup>Acne and Rosacea Research Laboratory, Seoul National University Hospital, Seoul, South Korea

<sup>#</sup>These 2 authors contributed equally to this work.

**Post-inflammatory erythema is a common result of acne inflammation and is cosmetically unacceptable without effective treatment. Fractional microneedling radiofrequency (FMR) has potential for treatment of post-inflammatory erythema. The aim of this study was to evaluate the efficacy and safety of this treatment. A retrospective chart review was undertaken of 25 patients treated with 2 sessions of radiofrequency at 4-week intervals and 27 patients treated with oral antibiotics and/or topical agents. Efficacy was assessed through an investigator's global assessment of photographs, and the analysis of erythema with image analysis software and photometric devices. Histological changes resulting from the treatment were evaluated by skin biopsy. FMR treatment resulted in significant improvements in erythema with no severe adverse effects. Histological study revealed a reduction in vascular markers and inflammation. FMR is a safe and effective treatment for post-inflammatory erythema, with potential anti-inflammatory and anti-angiogenic properties. Key words: acne; post-inflammatory erythema; fractional microneedling radiofrequency.**

Accepted Jun 3, 2015; Epub ahead of print Jun 10, 2015

Acta Derm Venereol 2016; 96: 87–91.

Dae Hun Suh, Department of Dermatology, Seoul National University College of Medicine, 101 Daehak-ro, Jongno-gu, Seoul 110-744, South Korea. E-mail: daehun@snu.ac.kr

Acne affects approximately 80% of adolescents and young adults (1, 2). Severe acne inflammation can result in subsequent erythema or hyperpigmentation and even permanent acne scarring. There are many reports of various treatments for pigmentation or acne scarring. However, there are few reports concerning treatment for residual erythema induced by acne inflammation. Post-inflammatory erythema (PIE) is very common following inflammatory acne and is often cosmetically unacceptable to patients (3). Patients usually have persistent red marks after clearing of the acute inflammation following acne treatment. Facial PIE improves with time, but very slowly, and in some cases, complete clearance of PIE cannot be achieved (4).

Radiofrequency devices, associated with preservation of the epidermis, and with fewer complications or

adverse effects and rapid recovery times, are becoming popular (5, 6). Fractional microneedling radiofrequency (FMR) delivers bipolar radiofrequency directly to the dermis using an array of microneedles (7). FMR has been reported to improve skin laxity and wrinkles (7–9). Bipolar radiofrequency has been reported to induce profound ne elastogenesis and neocollagenesis, which has been suggested as a potential mechanism of clinical efficacy (10). Moreover, FMR has been shown to have a therapeutic effect on inflammatory skin diseases, such as acne (11). We hypothesized that the dermal remodelling and anti-inflammatory effects of FMR may successfully treat PIE caused by persistent inflammation and destruction of the dermal matrix.

To date, no study has evaluated the efficacy of radiofrequency treatment in post-inflammatory erythema. The aim of this retrospective study was to evaluate the efficacy, safety and histological changes of FMR in post-inflammatory erythema. To the best of our knowledge, this is the first report of FMR for the treatment of PIE induced by acne inflammation.

## MATERIALS AND METHODS

### *Study design and subjects*

A retrospective chart review was undertaken of 52 patients who visited the Department of Dermatology, Seoul National University Hospital, South Korea, between August 2013 and February 2014. The study protocol was conducted in accordance with the Declaration of Helsinki and was approved by the Institutional Review Board of Seoul National University Hospital (No. 1407-136-597). Twenty-five subjects with PIE with few or no active acne lesions, who had been treated with FMR on the face, were included in the FMR-treated group. Twenty-seven patients with PIE and little or no active acne, who had been treated with oral and/or topical antibiotics, were included in the control group. Exclusion criteria were: patients with no photographs, hypertrophic or keloid scarring, patients being treated with any other treatment for acne scarring or erythema, including chemical or mechanical skin resurfacing, or use of topical or oral retinoids, for at least 3 months prior to first study. None of the patients underwent other acne scar treatments, including chemical or laser resurfacing during treatments.

### *Preparation and laser treatment*

All treatment procedures were performed by a single surgeon (SM). Topical anaesthesia with EMLA<sup>®</sup> (AstraZeneca, Södertälje, Sweden) was administered 30 min before laser treatment

commenced. The subjects in the FMR-treated group had received 2 sessions of FMR (INFINI®, Lutronic, Goyang, South Korea) treatment at 4-week intervals. The applicator tip comprised 49 insulated microneedles over an area of 1 cm<sup>2</sup>. The FMR system delivered the bipolar RF energy to the dermis at a frequency of 1 MHz, and at adjustable power levels ranging from 2.5 W to 50 W in 2.5 W increments. The exposure time, for which the RF energy was flowing per shot, could be adjusted from 10 ms to 1000 ms. In the current study, levels 2 (5 W) to 3 (7.5 W) were used, with exposure times of 50–70 ms. Three passes of treatment were done per each session. Ice packs were applied to reduce pain, followed by application of topical antibiotics, immediately after treatment. Subjects were allowed to use emollient and cosmetics from the next day onwards.

#### *Clinical outcome assessment*

On average, subjects in the FMR-treated group were followed up at 4-week intervals during the treatment period (2 treatment sessions) and 8 weeks after the final session of treatment. A standardized medical photograph was taken using identical camera settings (EOS 600D®, Canon, Tokyo, Japan) and lighting conditions. Assessment of the clinical photographs was conducted by 2 independent dermatologists (DHS and SYP). Efficacy was assessed by investigator's global assessment (IGA), which comprised 5 points associated with degree of improvement (grade 0: no improvement, grade 1: 0–25% improvement, grade 2: 26–50% improvement, grade 3: 51–75% improvement, grade 4: 76–100% improvement). Objective evaluation of erythema was routinely done via 2 photometric devices (Spectrophotometer CM-2002®, Konica Minolta, Tokyo, Japan; Derma-spectrometer®, Cortex Technology, Hadsund, Denmark). At every visit, patients were asked to report any adverse effects. Subjects' subjective assessment of therapeutic effectiveness was surveyed using a visual analogue scale (VAS) ranging from 0 (initial visit status of PIE) to 5 (complete clearance) for the FMR. Satisfaction was also measured by use of a VAS ranging from 0 to 10 (0: dissatisfied, 10: fully satisfied).

#### *Computer-aided erythema evaluation*

Many textural features for quantification of redness, including mean, standard deviation, smoothness, uniformity and entropy, were explored with a computer program, MATLAB® (The Math-Works, Inc., Natick, MA, USA) to distinguish colour differences in PIE from surrounding normal skin. In addition, many colour channel transformations, including grey channel, red channel, blue-red difference channel and a\* from L\*a\*b\*, were tested to assess the severity of erythema. Among them, smoothness using a\* channel was used in this study to maximize the description of colour difference. "Smoothness" is a measure of the smoothness of intensity according to the following formula:  $R=1-1/(1+\sigma^2)$ , where R is 0 for a region of contrast intensity and approaches 1 for regions with large excursions in the values of its intensity levels. The medical photographs, taken at baseline and 8 weeks after the second session of treatment in the FMR-treated group, and at baseline and after a similar term in the control group, were analysed with this program and smoothness values were obtained.

#### *Histopathology*

Skin specimens were obtained by punch (2-mm) biopsy from the cheek in 6 available patients in each group 8 weeks after the last session of treatment. Written informed consent was obtained from all subjects prior to skin biopsy. Sections were stained with haematoxylin-eosin (H&E) and  $\alpha$  smooth muscle actin ( $\alpha$ SMA). Tissue was also processed for immunohistochemical (IHC) staining for NF- $\kappa$ B, interleukin-8 (IL-8), and vascular endothelial cell growth

factor (VEGF) (Santacruz, Dallas, TX, USA). The intensity of IHC staining was assessed by use of an image analysis program (Leica QWin version 3.5.1, Leica Microsystems, Wetzlar, Germany).

#### *Statistical analysis*

Student's *t*-test was used to compare the differences between data obtained before and after FMR treatment (SPSS, version 12.0; SPSS Inc., Chicago, IL, USA). Statistical significance was accepted at *p*-values < 0.05.

## RESULTS

Twenty-five patients (12 men, 13 women) in the FMR-treated group and 27 patients (19 men, 8 women) in the control group were included in the study (*p* = 0.100). The participants all had Fitzpatrick skin types III–IV. The mean age of the subjects was 21.4 and 20.0 years in FMR-treated group and control group, respectively, with no significant difference. The mean baseline erythema indices were 19.6 and 19.3, and mean baseline a\* scale 9.9 and 9.7, respectively, with no significant differences between the 2 groups. The number of FMR treatment sessions was 2. There were no serious adverse effects that resulted in stopping treatment.

#### *Erythema improvement*

The grade of PIE improved in all patients (25/25) in the FMR-treated group and in 5 patients (5/27) in the control group. Inter-rater agreement was evaluated with  $\kappa$  statistics ( $\kappa$  value = 0.73, *p* < 0.001), demonstrating congruence between the 2 raters. There was a significant difference between the FMR-treated group and the control group in IGA score (*p* < 0.001). The mean IGA score for the FMR-treated group was 2.72, which indicates an improvement of approximately 45%. By contrast, the IGA score for the control group was 0.32 (a 7.5% improvement).

Photometric measurements of erythema revealed consistently decreased redness after FMR treatment compared with the baseline or control group (Fig. 1). There were significant reductions in the erythema index (*p* = 0.002) and a\* scale (*p* < 0.001) in the FMR-treated group compared with the control group.

Clinical photographs illustrating the improvement in redness in the FMR-treated group and the lack of improvement in the control group are shown in Fig. 2.

There were no severe adverse effects of FMR, other than mild adverse effects, such as pain during the procedure and erythema lasting for 3–5 days. No subjects dropped out due to erythema.

#### *Erythema analysis by software*

Smoothness from the a\* channel was calculated with the MATLAB® program. There were no statistical differences in smoothness between the 2 groups at

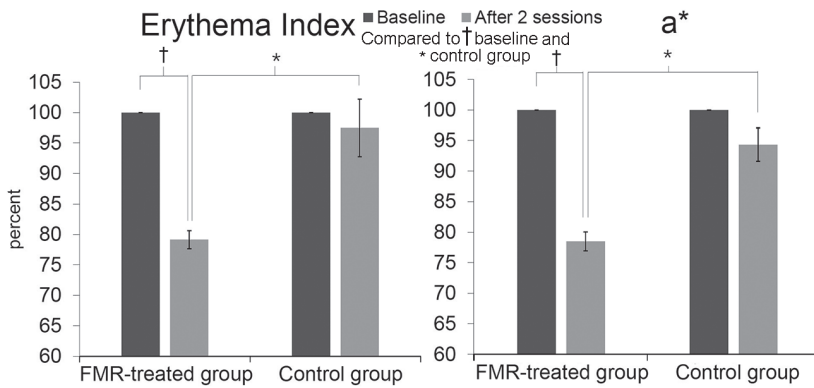


Fig. 1. Photometric measurements of the fractional microneedling radiofrequency (FMR)-treated group and control group. Decreased (A) erythema index and (B) a\* scale in the FMR-treated group after 2 sessions of treatment (\*, †  $p < 0.05$ ).

baseline (0.000219 vs. 0.000214) or between baseline and final evaluation in the control group (0.000214 vs. 0.000211). However, the FMR-treated group had a lower smoothness value from a\* channel than the control group at final evaluation (0.000138 vs. 0.000211;  $p = 0.008$ ), and a significant decrease in smoothness from a\* channel was seen in the treated group compared with baseline (0.000138 vs. 0.000219;  $p < 0.001$ ). The mean ratio of smoothness between final evaluation and baseline was significantly less in the FMR-treated (66.8%) than in the control group (104.3%) ( $p < 0.001$ ) (Fig. 3).

*Patient’s subjective assessment*

The satisfaction score and the therapeutic effectiveness for the FMR treatment were  $7.8 \pm 0.3$  and  $3.6 \pm 0.3$ , respectively. All subjects scored greater than 5 for satisfaction. Out of 25 subjects, 18 (71.4%) scored greater than 4 for effectiveness.

*Histological findings*

H&E staining revealed reduced inflammation, and  $\alpha$ SMA staining showed decreased microvessels after 2 ses-

sions of treatment with FMR (Fig. S1<sup>1</sup>). Reductions in IL-8, NF- $\kappa$ B and VEGF staining intensity were also observed 8 weeks after the second session of treatment. Image analysis showed significant differences in the mean area percentages for controls and FMR-treated patients, respectively; 20.3% and 9.7% for IL-8 ( $p = 0.049$ ), 15.7% and 7.5% for NF- $\kappa$ B ( $p = 0.032$ ), and 24.8% and 9.4% for VEGF ( $p = 0.008$ ), (Fig. 4).

**DISCUSSION**

There is no established treatment for acne-related PIE. FMR treatment was first introduced to improve skin aging; however, there have been several reports that it can improve acne inflammation (11, 12). Therefore, we conducted the present retrospective study to determine whether FMR can improve PIE associated with inflammation.

To date there have been few studies of PIE treatment. Pulsed-dye laser and non-ablative 1550-nm fractional laser has been shown to improve PIE (4, 12, 13). The present study demonstrated dramatic improvements in PIE according to the investigators’ and patient’s subjective assessments and evaluation using photometric devices and image analysis. The adverse effects of FMR were minimal. Facial PIE contributes to the emotional, social and psychological disability induced by acne (14). FMR could be an effective and safe treatment method of resolving this stressful skin condition.

Erythema has been evaluated in some previous studies via clinical photographs with computer-aided image analysis. Zhao et al. (15) analysed changes in erythema index after photodynamic therapy for port-wine stains using ImageJ (free software). The current study developed a novel variable smoothness for PIE

<sup>1</sup><http://www.medicaljournals.se/acta/content/?doi=10.2340/00015555-2164>

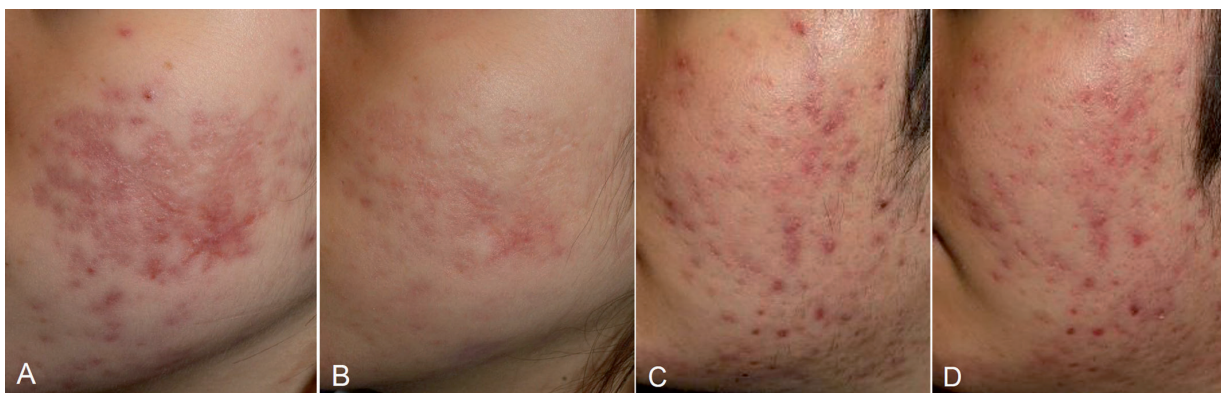

Fig. 2. Clinical photographs showing improvement in post-inflammatory erythema (PIE). The treated group showed improvement in redness 8 weeks after the second session of treatment (B) compared with baseline (A), whereas the control group showed no improvement (D) compared with baseline (C).

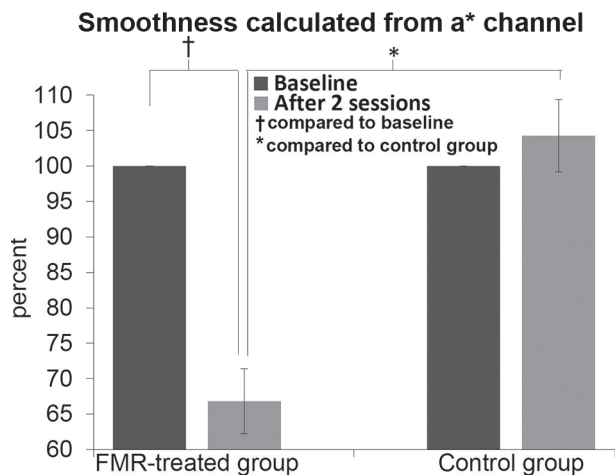


Fig. 3. Computer-aided erythema analysis. A variable "smoothness" showed reduction in post-inflammatory erythema (PIE) 8 weeks after the second session of treatment in the fractional microneedling radiofrequency (FMR)-treated group (\*, †  $p < 0.05$ ).

evaluation by assessing the colour differences between the lesional area and normal area of skin, and it showed similar degrees of improvement, as measured by photometric devices. Smoothness calculated from a\* channel could be used to evaluate macular erythema in other dermatoses, but its usefulness has not yet been evaluated objectively.

Previous studies on PIE treatment with other lasers have shown clinical improvement, but have not clearly demonstrated the mechanism of the effect. Bae-Harboe & Graber (3) used pulsed-dye laser to treat PIE and suggested that its effectiveness is attributable to targeting

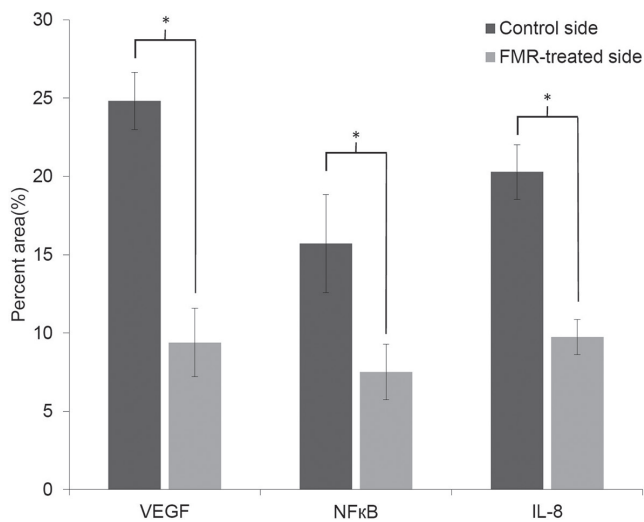


Fig. 4. Image analysis of immunohistochemistry staining of specimen from fractional microneedling radiofrequency (FMR)-treated group and control group. Significantly decreased intensity of vascular endothelial cell growth factor (VEGF) was observed after FMR treatment (compared with control group,  $p = 0.008$ ). Significant down-regulation of NF-κB (compared with control group,  $p = 0.032$ ) and interleukin (IL)-8 (compared with control group,  $p = 0.049$ ), which is associated with inflammatory reaction, was shown after FMR treatment (\* $p < 0.05$ ).

haemoglobin and small-diameter vascular processes. Park et al. (4) proposed that 1550-nm fractional laser treatment targets tissue water and causes photothermal destruction of dermal vasculature, resulting in improvement in erythema. A suggested mechanism for FMR is remodelling of the dermal structure and decreased sebaceous gland activity due to the thermal effect of radiofrequency (16, 17). In the present study, decreased intensity of NF-κB, IL-8, and VEGF was observed under IHC staining. We hypothesize that inflammation may contribute to neovasculogenesis, resulting in residual erythema after resolution of active acne lesions. Therefore, FMR could improve PIE by modulating inflammatory and vascular components.

NF-κB plays a key role in regulating the immune reaction, and controls many genes involved in inflammation. NF-κB is chronically active in many inflammatory diseases (18). NF-κB can activate IL-8 and VEGF expression via binding to NF-κB sites of the promoter of these genes (19). NF-κB inhibitors lower the levels of VEGF production, and overexpression of NF-κB inhibitor (IκBa) results in decreased VEGF levels (20, 21). IL-8 can also up-regulate VEGF expression via various molecular pathways (20). In tumour formation, the tumourigenic process can be enhanced by inflammatory cytokines, by up-regulating angiogenesis mediators, such as IL-8 and VEGF (21). Moreover, the vascular changes associated with angiogenesis could occur not only in cancer but also in other diseases, including cardiovascular disease, rheumatoid arthritis, hypersensitivity and asthma (21).

Although the mechanism by which FMR regulates NF-κB or IL-8 is unknown, we suggest that FMR treatment may reduce inflammation of the PIE lesion, and this is supported by decreased expression of NF-κB, resulting in down-regulation of VEGF via a direct or indirect (via lowering IL-8) pathway.

This study was done by retrospective review. Thus, we tried to avoid information bias of study results. First, clinical assessment was done by independent two dermatologists. We also evaluated the inter-rater agreement by Cohen's kappa test. Second, objective measurements using photometric devices were done. Third, clinical photographs were analyzed by digital image processing program (MATLAB®). However, there is still more risk of selection bias compared with prospective study.

In conclusion, PIE is an under-studied sequelae of acne, and its clinical significance can be overlooked compared with active acne or depressive acne scarring. This study demonstrates that FMR is a safe and effective method for PIE treatment; its effectiveness is proven by several objective and subjective assessments. FMR treatment could improve erythema by reducing inflammation and abnormal vessel proliferation. Anti-inflammatory and anti-angiogenic effects of FMR may have therapeutic effects in skin diseases other than

PIE. Further research may reveal other indications for FMR treatment and other options for treatment of PIE.

ACKNOWLEDGEMENT

This work was supported by the National Research Foundation of Korea (NRF) grant funded by the Korea government (MSIP) (No. 2014R1A2A1A11049397).

*The authors declare no conflicts of interest.*

REFERENCES

1. Goodman G. Acne – natural history, facts and myths. *Aust Fam Physician* 2006; 35: 613–616.
2. Leyden JJ. Therapy for acne vulgaris. *N Engl J Med* 1997; 336: 1156–1162.
3. Bae-Harboe YS, Graber EM. Easy as PIE (postinflammatory erythema). *J Clin Aesthet Dermatol* 2013; 6: 46–47.
4. Park KY, Ko EJ, Seo SJ, Hong CK. Comparison of fractional, non-ablative, 1550-nm laser and 595-nm, pulsed dye laser for the treatment of facial erythema resulting from acne: a split-face, evaluator-blinded, randomized pilot study. *J Cosmet Laser Ther* 2014; 16: 120–123.
5. Bassichis BA, Dayan S, Thomas JR. Use of a nonablative radiofrequency device to rejuvenate the upper one-third of the face. *Otolaryngol Head Neck Surg* 2004; 130: 397–406.
6. Biesman BS, Pope K. Monopolar radiofrequency treatment of the eyelids: a safety evaluation. *Dermatol Surg* 2007; 33: 794–801.
7. Alexiades-Armenakas M, Rosenberg D, Renton B, Dover J, Arndt K. Blinded, randomized, quantitative grading comparison of minimally invasive, fractional radiofrequency and surgical face-lift to treat skin laxity. *Arch Dermatol* 2010; 146: 396–405.
8. Hruza G, Taub AF, Collier SL, Mulholland SR. Skin rejuvenation and wrinkle reduction using a fractional radiofrequency system. *J Drugs Dermatol* 2009; 8: 259–265.
9. Willey A, Kilmer S, Newman J, Renton B, Hantash BM, Krishna S, et al. Elastometry and clinical results after bipolar radiofrequency treatment of skin. *Dermatol Surg* 2010; 36: 877–884.
10. Hantash BM, Ubeid AA, Chang H, Kafi R, Renton B. Bipolar fractional radiofrequency treatment induces neo-

- elastogenesis and neocollagenesis. *Lasers Surg Med* 2009; 41: 1–9.
11. Lee SJ, Goo JW, Shin J, Chung WS, Kang JM, Kim YK, et al. Use of fractionated microneedle radiofrequency for the treatment of inflammatory acne vulgaris in 18 Korean patients. *Dermatol Surg* 2012; 38: 400–405.
12. Yoon HJ, Lee DH, Kim SO, Park KC, Youn SW. Acne erythema improvement by long-pulsed 595-nm pulsed-dye laser treatment: a pilot study. *J Dermatolog Treat* 2008; 19: 38–44.
13. Glaich AS, Goldberg LH, Friedman RH, Friedman PM. Fractional photothermolysis for the treatment of postinflammatory erythema resulting from acne vulgaris. *Dermatol Surg* 2007; 33: 842–846.
14. Mallon E, Newton JN, Klassen A, Stewart-Brown SL, Ryan TJ, Finlay AY. The quality of life in acne: a comparison with general medical conditions using generic questionnaires. *Br J Dermatol* 1999; 140: 672–676.
15. Zhao Y, Tao J, Tu P. Quantitative evaluation of efficacy of photodynamic therapy for port-wine stains using erythema index image analysis. *Photodiagnosis Photodyn Ther* 2013; 10: 96–102.
16. Ruiz-Esparza J, Gomez JB. Nonablative radiofrequency for active acne vulgaris: the use of deep dermal heat in the treatment of moderate to severe active acne vulgaris (thermotherapy): a report of 22 patients. *Dermatol Surg* 2003; 29: 333–339.
17. Elsaie ML, Choudhary S, Leiva A, Nouri K. Nonablative radiofrequency for skin rejuvenation. *Dermatol Surg* 2010; 36: 577–589.
18. Monaco C, Andreacos E, Kiriakidis S, Mauri C, Bicknell C, Foxwell B, et al. Canonical pathway of nuclear factor kappa B activation selectively regulates proinflammatory and prothrombotic responses in human atherosclerosis. *Proc Natl Acad Sci U S A* 2004; 101: 5634–5639.
19. Huang S, Robinson JB, Deguzman A, Bucana CD, Fidler IJ. Blockade of nuclear factor-kappaB signaling inhibits angiogenesis and tumorigenicity of human ovarian cancer cells by suppressing expression of vascular endothelial growth factor and interleukin 8. *Cancer Res* 2000; 60: 5334–5339.
20. Charalambous C, Pen LB, Su YS, Milan J, Chen TC, Hoffman FM. Interleukin-8 differentially regulates migration of tumor-associated and normal human brain endothelial cells. *Cancer Res* 2005; 65: 10347–10354.
21. Angelo LS, Kurzrock R. Vascular endothelial growth factor and its relationship to inflammatory mediators. *Clin Cancer Res* 2007; 13: 2825–2830.